

Nasal Cornu cutaneum in Indian daily-wage worker - A case report

¹Surya Singh, Consultant Oral and Maxillofacial Surgeon, Shreeji Multispeciality hospital, Dhrangadhra, India.

²Palak Mehta, Consultant Oral and Maxillofacial Surgeon, Shreeji Multispeciality hospital, Dhrangadhra, India.

Corresponding Author: Surya Singh, Consultant Oral and Maxillofacial Surgeon, Shreeji Multispeciality hospital, Dhrangadhra, India.

Citation of this Article: Surya Singh, Palak Mehta, “Nasal Cornu cutaneum in Indian daily-wage worker - A case report”, IJDSIR- November - 2022, Vol. – 5, Issue - 6, P. No. 190– 193.

Copyright: © 2022, Surya Singh, et al. This is an open access journal and article distributed under the terms of the creative commons’ attribution non-commercial License. Which allows others to remix, tweak, and build upon the work non-commercially, as long as appropriate credit is given and the new creations are licensed under the identical terms.

Type of Publication: Case Report

Conflicts of Interest: Nil

Abstract

Cornu cutaneous is an entity often found to be associated with several premalignant & malignant skin conditions. It is popularly known as a cutaneous horn. It is a slow-developing lesion that becomes firm and conical with time resembling an animal's horn. Generally, the lesion is asymptomatic thus many patients report later the sooner after developing it. Excisional biopsy is currently the main treatment for such a lesion.

Keywords: Cutaneous horn, Skin cancer, Premalignant lesions, Hyperkeratosis, Photo allergy

Introduction

The lesion is typically a conical projection mounted on a base of hyperproliferative skin derived from densely packed keratinaceous material. ⁽¹⁾ For the lesion to be termed a “horn,” the height of the lesion must be greater than at least one-half of its greatest diameter. ⁽²⁾ Benign and malignant pathological changes are seen in this lesion due to the hyper-proliferation of compact keratin. These are usually seen in elderly persons with a

protuberant mass of keratin that resembles the horn of an animal. ⁽³⁾

Cutaneous horns are conical-shaped protuberances formed by very dense keratin seen in areas chronically damaged by the sun. Due to the lack of a central bone, they differ from animal horns. These lesions are seen on all parts of the body, with predominance on the face and scalp representing 30% of all occurrences. It causes aesthetic discomfort and can be dangerous if the base of the horn is cancerous. The incidence of malignancy is much higher in the facial region hence surgery is the most appropriate treatment. Histopathological examination of the base of the horn is widely recommended to exclude malignancy. ⁽⁴⁾

Case report

A 42-year-old female daily wage worker reported to our department with a complaint of growth on her nose. She gave a history of a slow gradual increase of the lesion; however, it was painless. She mentioned working in a setting where she has direct sunlight exposure for extended periods of the day. On examination, a conical

projection, dark greyish brown, approximately 2 cm long, and 1.5 cm in maximum diameter was found over the Left nasal dorsum (Figure 1). The lesion was hard in consistency. It had a smooth surface near the apex which became rough near the base of the lesion. There was no lymph node enlargement. An excisional biopsy was performed and the sample was sent for pathological evaluation. The results of the biopsy revealed a Cornu Cutaneum with no evidence of dysplasia or malignancy. The patient healed completely with minimal scarring.

Investigations

Samples, inclusive of the base of the lesion were sent for histopathological evaluation.

Differential diagnosis

Differential diagnosis includes verruca, capillary haemangioma, basal cell carcinoma, trichilemmal carcinoma, and Kaposi's sarcoma.⁽⁵⁾

Treatment

Treatment consists of an excisional biopsy of the cutaneous horn with margins of unaffected skin (Figure 2). Depending on the location Moh's surgery may be required.⁽⁵⁾ Shaving is an option only when there is no possibility of total excision and in sensitive cosmetic areas. Electrocauterization, cryotherapy, and laser ablation are alternatives.⁽⁶⁾

Histopathology

Sections revealed lesion to be composed of markedly hyperkeratotic squamous epithelium with the presence of kerato hyaline granules. A mild chronic inflammatory infiltrate was present in the subepithelial region. No evidence of dysplasia or malignancy (Figure 3)

Discussion

The earliest description of cutaneous horns was given by Everard Home in 1791.⁽⁷⁾ These lesions arise in both areas exposed to the sun as well as in sun-protected areas. The most common sites are on the upper part of

the face, the nose, scalp, lips, eyelids, ear cartilage, neck, shoulders, forearms, and the back of the hands.^(1,8)

The base of the horn may be flat, nodular, or crateriform and its length can be several millimetre's long. The horn is made up of compacted keratin. Malignant changes in these lesions are mostly seen in the head and neck region hence biopsy examination is warranted. This may be attributed to actinic changes because of exposure to ultraviolet radiation.⁽⁷⁾

Malignancy is present in 16-20% of cases, with squamous cell carcinoma being the most common type. Tenderness at the base of the lesion and lesions of larger size favour malignancy. Most cutaneous horns arise from actinic keratoses but they may also result from seborrheic keratoses, warts, kerato acanthomas, squamous cell carcinomas, and basal cell carcinomas.

Histologically, there is a greatly thickened stratum corneum with scattered areas of parakeratosis. The horn at the base will display features characteristic of the pathologic process responsible for the development of the horn.

Excisional biopsy and histopathological examination of the lesion is recommended to rule out malignancy. Malignancies should be excised with appropriate margins and evaluated for metastasis.⁽³⁾

The pathogenesis of the cutaneous horn is not fully understood. The horn itself is cornified debris with no clinical consequence. These lesions can be of various sizes or in different shapes, like cylindrical, conical, straight, curved, and pointed.

Definitive treatment of such lesions is based on the final pathological diagnosis. In the case of benign/premalignant lesions, wide local excision with close follow-up should be indicated. Especially in cases of malignancy like squamous cell carcinoma type, a neck dissection may be associated often with radiotherapy or

chemotherapy. There are also different treatment approaches such as carbon dioxide or neodymium-doped yttrium aluminium garnet laser excision, with varying success. ⁽⁴⁾

Conclusion

Cornu Cutaneum is a protrusion of keratinized material that rises above the surface of the skin. The important concern in this condition is not the horn itself, which is just dead keratin, but rather the nature of the underlying disease. However, the treatment modality always remains surgical removal followed by histopathological examination of these skin horns to confirm an accurate diagnosis and to ensure aesthetic comfort.

References

1. Harith Akram, Shan Shan Jing, Srinivas Murahari, Karoly David, Cutaneous horn: case report, *British Journal of Oral and Maxillofacial Surgery*, Volume 49, Issue 1, 2011, Pages 73-75, ISSN 0266-4356, <https://doi.org/10.1016/j.bjoms.2009.09.019>.
2. Srivastava G, Srivastava G. Cornu cutaneum – Past and present. *Cosmo Derma* 2021; 1:33.
3. Agirgol, S et al. “Giant Cornu Cutaneum Superimposed on Basal Cell Carcinoma.” *The West Indian medical journal* vol. 64,4 (2015): 438-40. doi:10.7727/wimj.2014.056
4. Salissou Iro, Amina Maadane, FaiÅşal Slimani, Facial cutaneous horn in three different conditions: A highlight of a malignancy risk, *International Journal of Surgery Case Reports*, Volume83,2021,105 999, ISSN 2210 -2612, <https://doi.org/10.1016/j.ijscr.2021.105999>.
5. Haddad CJ, Haddad-Lacle JEM Cutaneous horn: get to the bottom of it. *Case Reports* 2014;2014: bcr 2014 204447.
6. Copcu, Eray et al. “Cutaneous horns: are these lesions as innocent as they seem to be?” *World journal*

of surgical oncology vol. 2 18. 3 Jun. 2004, Doi: 10.1186/1477-7819-2-18

7. Mir MA, Mahmud AA, Yaseen M, et al. Cutaneous Horn: A devil not only in appearance. *Plast Surg Case Studies*. 2016;2(3):51-52.

8. Oded Nahlieli, Abraham M Baruch in, Yehoshua Shapira, David Ben-Dor, Cutaneous horns occurring on the head and neck region: Report of four cases and review of the literature, *Journal of Oral and Maxillofacial Surgery*, Volume 55, Issue 11,1997, Pages 1309-1311, ISSN 0278-2391, [https://doi.org/10.1016/S0278-2391\(97\)90190-7](https://doi.org/10.1016/S0278-2391(97)90190-7).

Legend Figures

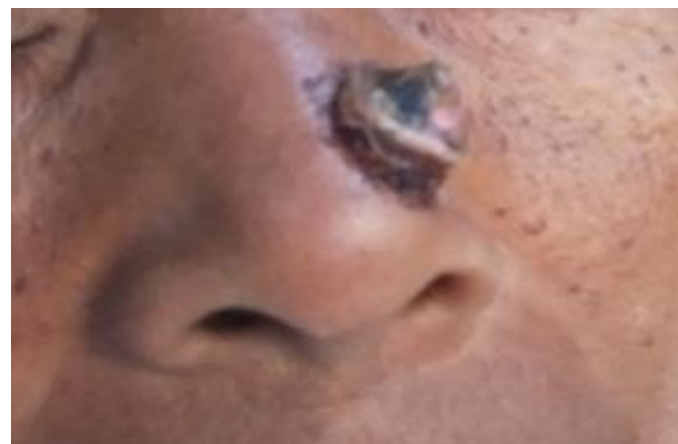

Figure 1: Growth on left nasal dorsum.

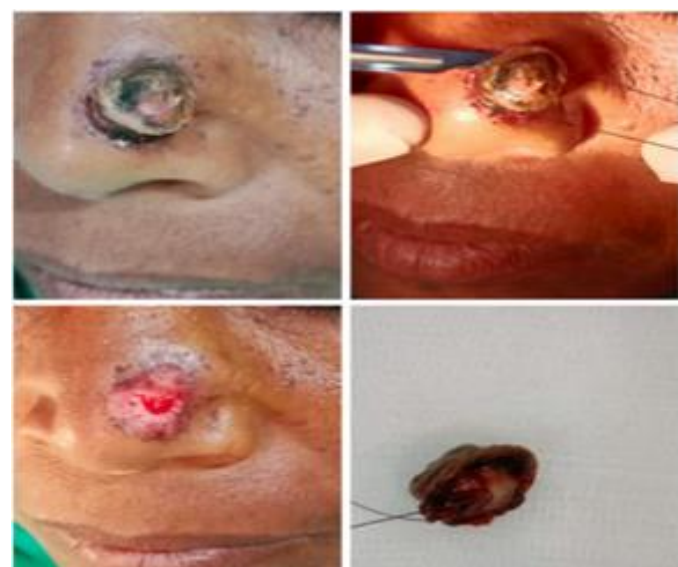

Figure 2: Excisional biopsy done and specimen sent for histopathological evaluation

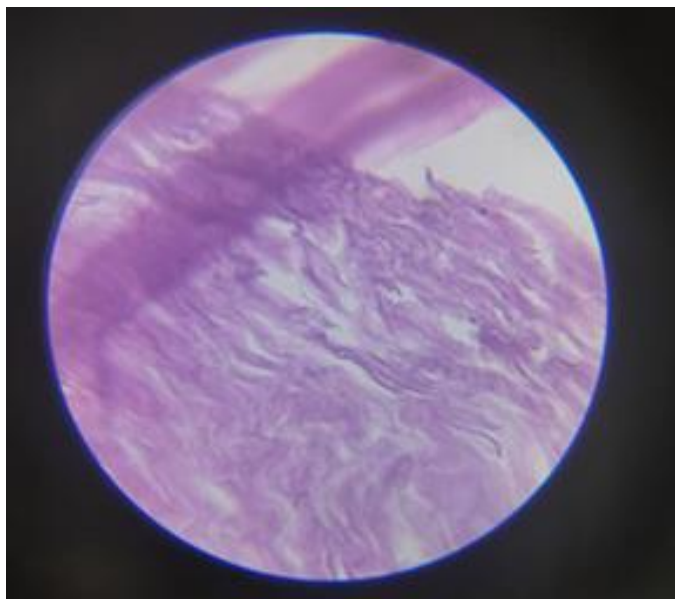


Figure 3: H and E - stained specimen slide showing hyper keratotic squamous epithelium with kerato - hyaline granules