

Case Report on: Maxillary Trial Denture to Overcome Radiation Induced Xerostomia

Dr. Ramseh Kumar Shetty, General Practitioner, City Dental Hospital, Bangalore, Karnataka, India

Corresponding Author: Dr. Ramseh Kumar Shetty, General Practitioner, City Dental Hospital, Bangalore, Karnataka, India

Type of Publication: Case Report

Conflicts of Interest: Nil

Abstract

Xerostomia is a subjective symptom of dry mouth. It can occur as a part of systemic disease, drug induced side effect or following therapeutic radiation therapy to the head and neck region. The primary complication faced by these xerostomic patients is the difficulty in retention of removable dentures. It is important to recognize that prosthodontic management of these patients requires special attention and care. In an attempt to overcome the presence of xerostomia, several techniques of introducing reservoirs into the dentures containing salivary substitutes have been proposed. Following case report presents a more simplified approach for the construction of a reservoir in the maxillary denture, specifically in patients where other treatment modalities have failed. This technique provided excellent lubrication to oral tissues, hygienic for the patient and utilized routine denture base material.

Keywords: Xerostomia, Dry Mucosa, Acrylisation, Denture, Artificial Saliva, Mandibular Denture

Introduction

Xerostomia is a common complaint compromising oral functions and quality of life¹. Aetiology of xerostomia is multifactorial such as Sjogren's syndrome, drug induced side effects, salivary gland diseases, head and neck radiation side effects and medical illness such as diabetes². The severity of the problem increases in an edentulous patient suffering from xerostomia because of the extreme

discomfort in wearing the dentures. Presence of sufficient amounts of saliva within denture and tissue interface is essential. In the absence of adequate saliva, a denture will not attach to the tissues as a result of the loss of surface tension³ thereby diminishing the retention of the dentures^{4, 5, 6}. Depending on the underlying etiology leading to xerostomia, various treatment options are available. These range from changes in dietary pattern, artificial salivary stimulants and use of salivary substitute⁷. An effective solution in edentulous patients with xerostomia is to achieve constant salivary substitute concentration into the patient's mouth without affecting the patient's daily routine⁸. A perpetual flow of artificial saliva can be accomplished with the help of a reservoir embedded in a maxillary or mandibular denture. It has been proposed that incorporation of these reservoirs containing salivary substitutes into dentures can be offered to these patients, after the failure of all available treatment options². These salivary substitutes enhance lubrication and act as wetting agent for dry mucosa. They also provide symptomatic relief and thus promote the retention of an artificial prosthesis. The continuous delivery of these substitutes can occur over a longer period by using saliva reservoir in edentulous xerostomic patients⁹. This case report describes a method for the fabrication of reservoir in maxillary denture to overcome the problem of xerostomia after the failure of other treatment modalities.

Case Report

60 year old male patient presented to the Department of Prosthodontics, City Dental Hospital, Bangalore, Karnataka, India with chief complaints of dryness of mouth and discomfort while speaking and eating. The patient had a history of smoking 20 cigarettes/day and daily alcohol abuse since last 20 years. His past medical history included stage III squamous cell carcinoma left tonsillar pillar for which he had had radiation therapy 19 months previously. He also had a history of hypertension and non-insulin dependent diabetes mellitus and was on treatment for the same. Extra-oral examination revealed cracks at the corner of the mouth. Intraoral inspection disclosed edentulous maxillary and mandibular ridges, areas of inflammation, dryness of tongue, and minimal saliva in the oral cavity (Fig. 1a, 1b). As initial treatment, the patient's family doctor was contacted and his hypertensive medications were altered. Multivitamin supplementations and use of salivary substitutes (methyl cellulose) were advised. General measures included frequent sips of water to overcome the dryness and associated discomfort.

Fabrication of Upper Complete Denture with Salivary Reservoir

1. The primary impression was made in irreversible hydrocolloid. Putty rubber base impression material was utilized for primary impressions. Custom trays were fabricated, border moulding was done, and secondary impressions were made in light body elastomeric impression material (Aquasil Ultra LV Dentsply Caulk).
2. Occlusal rims were fabricated and jaw relation was obtained. Teeth were arranged on occlusal rims and Try-in was done.
3. Two sheets of modeling wax of 2mm thickness were adapted over the palatal surface of maxillary denture base

(Fig. 2). The reservoir was created by removing the centre of the palatal wax. In the centre of the palate, putty was adapted to occupy the space needed for the reservoir (Fig. 3, 4). Extra 2mm bulk of wax was added over this putty in a proper manner to exactly fit the reservoir. This lid was cured separately and denture was cured in another flask simultaneously. Heat cure acrylic resin (trevalon, dentsply) was used for the processing of this assembly (Fig. 5).

4. After acrylisation, finishing was done. The processed lid was permanently attached to the reservoir area with the help of self-cure resin (Fig. 6). The final assembly was polished. One inlet and 3 outlet holes of a size similar to 19 gauge and 26 gauge needles respectively were made on the palatal aspect of the denture behind the central incisor area.

5. Artificial saliva substitute (wet mouth, ICPA) was then used for filling the reservoir space.

6. The patient was taught about the filling and cleaning of reservoir space. The patient was recalled after 24 hours, 1 week, monthly and every 6 months thereafter. The patient was satisfied with the prosthesis in terms of relief from symptoms of dry mouth as well as improved dietary intake.

Discussion

A healthy person produces saliva in the range of 1 – 1.5 litres per day. The unstimulated flow of saliva is mainly from submandibular gland constituting about 65%, 20% from parotid gland, 7% - 8% from sublingual gland, and less than 10% from minor salivary glands while stimulated flow of saliva is primarily from parotid gland being responsible for more than 50% of total salivary secretions^{3, 10}. Salivary flow value of less than 0.1 ml/min is considered as xerostomia³. Xerostomia is documented as important acute and late radiation therapy sequelae affecting the quality of life of these patients¹¹. The exact

mechanism responsible for radiation-induced xerostomia is unknown. It is thought that it occurs as a result of damage to the blood supply or signal transduction system damage or destruction of the gland itself because most of the salivary glands are included in the radiation fields for head and neck malignancy^{12, 13}. Several causes have been held responsible for xerostomia such as anxiety, medications, reduced mastication, autoimmune diseases, or radiation treatment as in our case¹⁴.

Efforts to reduce the severity of radiation-induced xerostomia include stimulants of salivary gland function (e.g. parasympathetic drugs as pilocarpine and bethanechol), xerostomia prevention strategies (e.g. amifostine), use of salivary substitutes for symptomatic relief and modern radiation therapy techniques (e.g. intensity modulated radiotherapy)¹⁵. However, these currently available treatment options for xerostomia are not very successful in bringing substantial comfort for the patient¹⁶. For an edentulous patient with normal salivary flow rehabilitation with dentures is possible. On the other hand, the denture is poorly tolerated by an edentulous patient with diminished salivary flow due to the lack of saliva between the denture/tissue interface⁹. Several methods for incorporating salivary reservoir in complete and partial dentures have been described in the literature.

Toljanic and Zucuskie reported several advantages of the salivary reservoir in the maxillary denture over the mandibular denture. These included: sufficiently large size of the reservoir, allowing salivary flow directly to the whole mouth and food in the floor of mouth does not block the draining holes. Contradictory to this, Sinclair et al. reported mandibular denture as more stable because of the effect of gravity and direct delivery of the salivary agent to the mucosa¹⁷. Our case report described approach of incorporating reservoir containing salivary substitute in the maxillary denture as an attractive option with multiple

advantages. The access to this type of reservoir is easy, hygienic and provided good lubrication of oral tissues. Another benefit of this technique is a fabrication of maxillary reservoir denture requires routine denture material.

The dentures and the reservoir require meticulous cleaning and refilling of the chamber is undertaken by the patient using disposable syringes.

Conclusions

The interest of this case lies in the specialized technique of fabricating maxillary saliva reservoir denture for the management of xerostomia in a cured patient of carcinoma oropharynx. This technique is simple, no special denture material is required, and keeps the oral tissues moist. However, there is a need to develop reservoir chambers in an attempt to achieve the even more controlled release of artificial saliva, making the treatment more acceptable to patients.

References

1. Brosky ME. The role of saliva in oral health: Strategies for prevention and management of xerostomia. *J Support Oncol* 2007; 5: 215-25.
2. Verma K, Gowda EM, Pawar VR, Kalra A. Salivary reservoir denture – A novel approach to battle xerostomia. *Med J Armed Forces India* 2015; 71: S190-3.
3. Arora V, Kumar D, Legha VS, Kumar KV. Management of xerostomia patient with salivary reservoir designed in upper complete denture and lower cast partial denture. *J Contemp Dentistry* 2014; 4: 56-9.
4. Hallikerimath RB, Jain M. Managing the edentulous dry mouth: The two part mandibular denture. *J Indian Prosthodont Soc* 2012; 12: 51-4.
5. Burhanpurwala MA, Magar S, Bhandari AJ, Gangadhar SA. Management of an edentulous patient having xerostomia with artificial saliva reservoir denture. *J Indian Prosthodont Soc* 2009; 9: 92-5.

6. Arslan A, Orhan K, Canpolat C, Delilbasi C, Dural S. Impact of xerostomia on oral complaints in a group of elderly Turkish removable denture wearers. *Arch Gerontol Geriatr* 2009; 49: 263-67.

7. Joseph AM, Joseph S, Mathew N, Koshy AT. Functional salivary reservoir in maxillary complete denture – technique redefined. *Clin Case Rep* 2016; 4: 1082-7.

8. Lagdive SB, Umbarkar RB, Lagdive SS, Gandhage DS, Bhandari AJ, Gangadhar SA. Dentures as artificial saliva reservoirs in the irradiated edentulous cancer patient with xerostomia. *Indian J Basic Applied Med Res* 2011; 1: 31-7.

9. Upadhyay SR, Kumar L, Rao J. Fabrication of a functional palatal saliva reservoir by using a resilient liner during processing of a complete denture. *J Prosthet Dent* 2012; 108: 332-5.

10. Humphrey SP, Williamson RT. A review of saliva: Normal composition, flow, and function. *J Prosthet Dent* 2001; 85: 162-9.

11. Mittal K, Singh AB, Bala N. Radiotherapy induced xerostomia in head and neck cancer patients. *Int J Sci Res* 2015; 5: 1-4.

12. Jaguar GC, Prado JD, Campanha D, Alves FA. Clinical features and preventive therapies of radiation-induced xerostomia in head and neck cancer patient: a literature review. *Applied Cancer Res* 2017; 37: 31.

13. Wada A, Uchida N, Yokokawa M, Yoshizako T, Kitagaki H. Radiation-induced xerostomia: Objective evaluation of salivary gland injury using MR sialography. *Am J Neuroradiol* 2009; 30: 53-8.

14. Ladda R, Kasat VO, Gangadhar SA, Baheti S, Bhandari AJ. Reservoir complete denture in a patient with xerostomia secondary to radiotherapy for oral carcinoma: a case report and review of literature. *Ann Med Health Sci Res* 2014; 4: 271-5.

15. Eisbruch A, Rhodus N, Rosenthal D, Murphy B, Rasch C, Sonis S, et al. the prevention and treatment of radiotherapy-induced xerostomia. *Seminars in Radiat Oncol* 2003; 13: 302-8.

16. Toljanic JA, Zucuskie TG. Use of a palatal reservoir in denture patients with xerostomia. *J Prosthet Dent* 1984; 52: 540-4.

17. Sinclair GF, Frost PM, Walter JD. New design for an artificial saliva reservoir for the mandibular complete denture. *J Prosthet Dent* 1996; 75: 276-80.

List of Case Report Figure

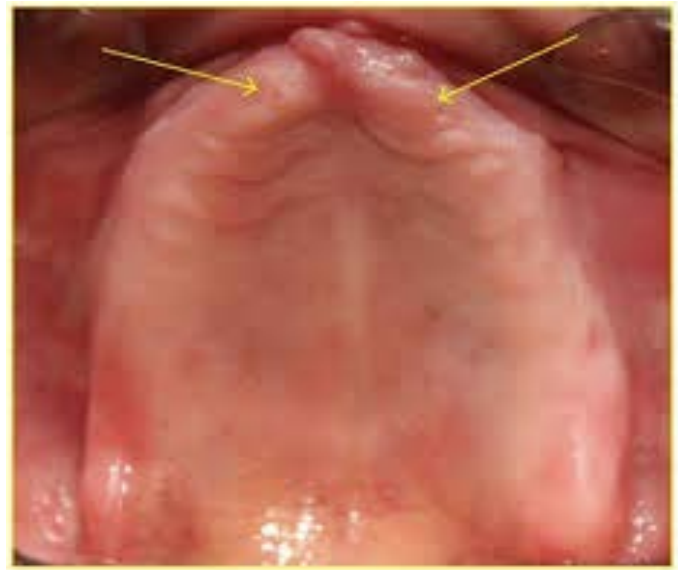

Fig 1a: Edentulous Maxillary Ridge

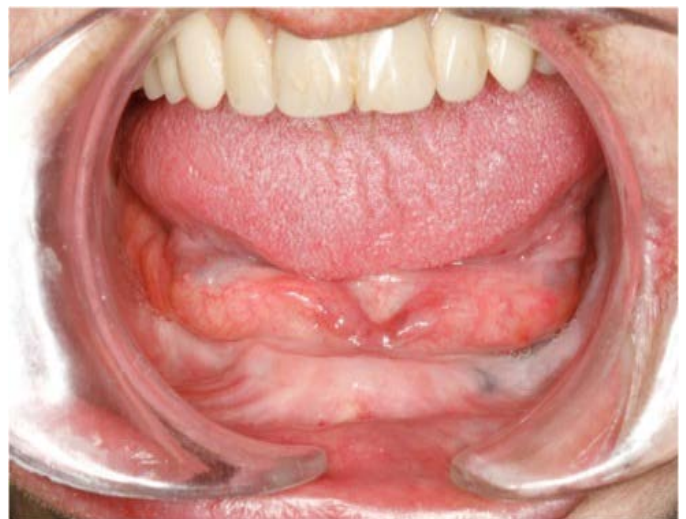

Fig 1b: Edentulous Mandibular Ridge

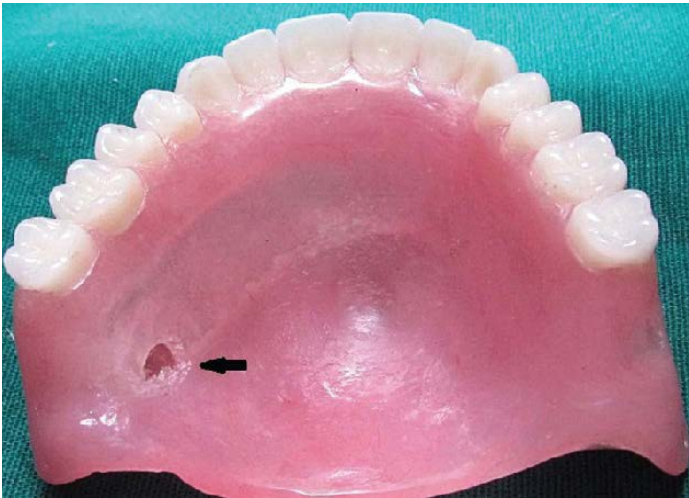


Fig 2: 2mm thick modeling wax

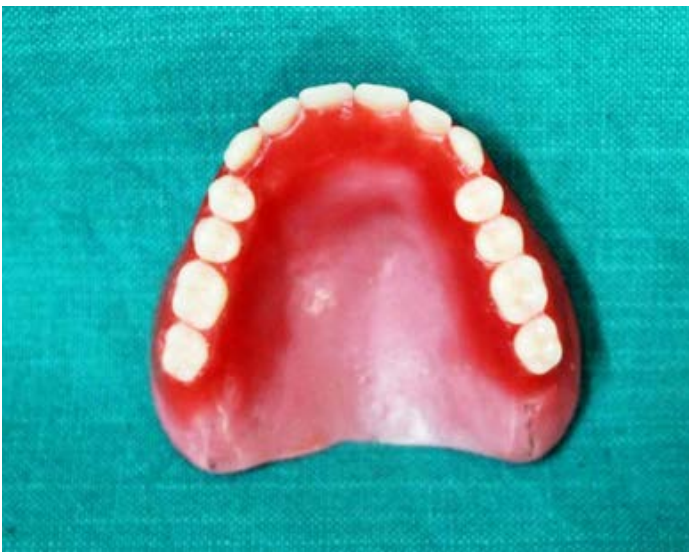

Fig 3: Palatal wax removed

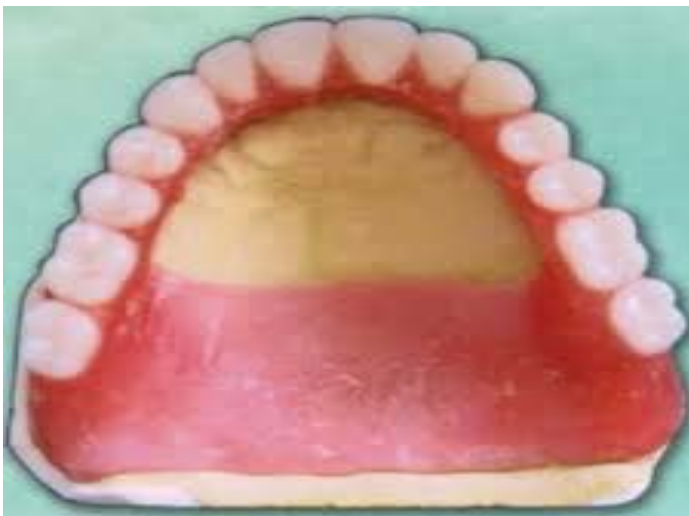

Fig 4: Putty adapted over central area to form the reservoir

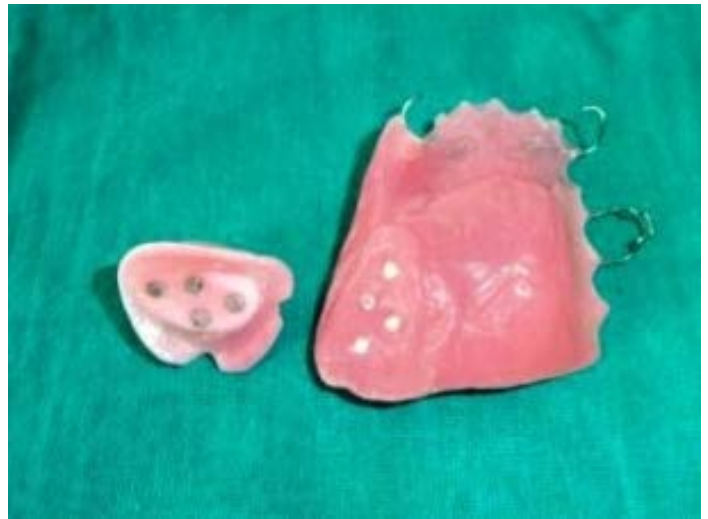

Fig 5: Lid and the denture cured separately

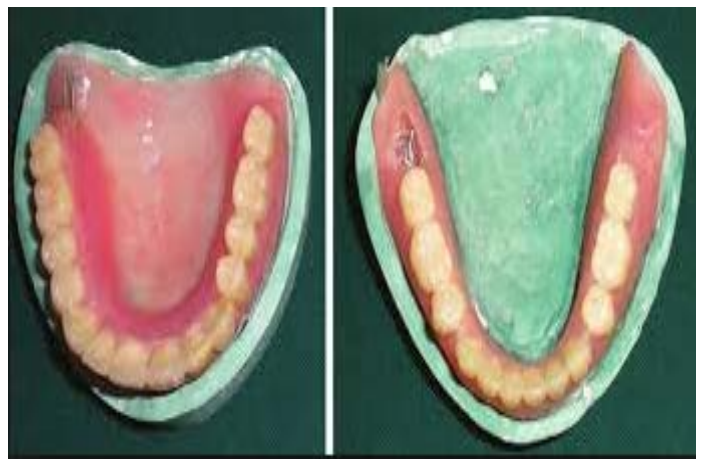

Fig 6: Lid permanently attached with autopolymerizing acrylic resin